



Do you have Spacing between your teeth/missing teeth/ crowding in your front teeth/excessive gums showing/old bad crowns which you happen to think are the norm???? Read On... this is just for you....

Most people feel they have to just bear and live with such teeth and stop smiling altogether but some

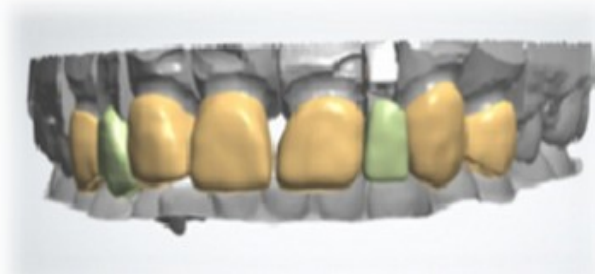
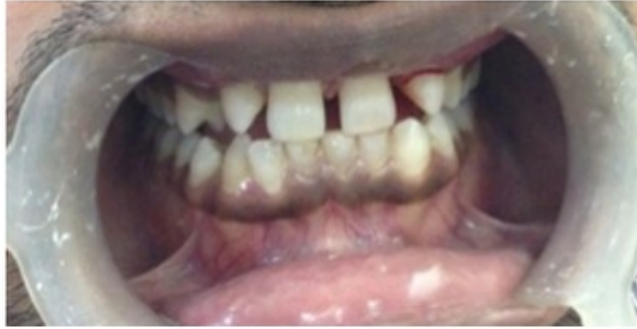proactive people opted for a change that changed their whole lifestyle and upped their achievements and how; you say?!...

Here are a few cases that cover the spectrum of cosmetic /Aesthetic dentistry that were a challenge even to our team of dental specialists to bring to life the patient's vision for a million dollar smile that could light up their eyes and other's hearts....

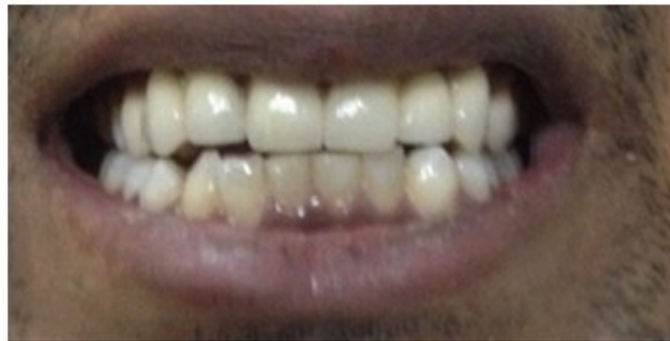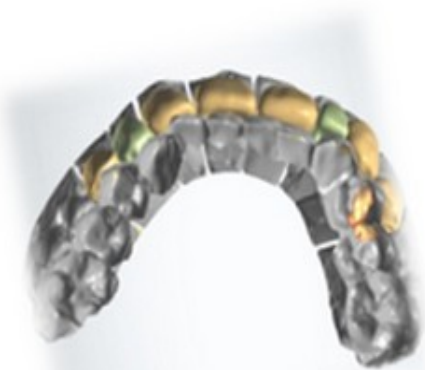
CASE 1: Congenitally Missing Lateral Incisors (From Birth)

This patient had altogether **missing lateral incisors (2 front teeth)** from birth and protruding, malpositioned canines and he just came and said "Dr... I want normal teeth, just like the others, something natural looking. I just want a perfect smile...What do I do?".

As he was missing two teeth and the adjacent two teeth had partially occupied its space, Space distribution was a great challenge. We had to digitally design the position of the new crowns to replace the missing teeth, so that we could ensure that the objectives of the patient were met.



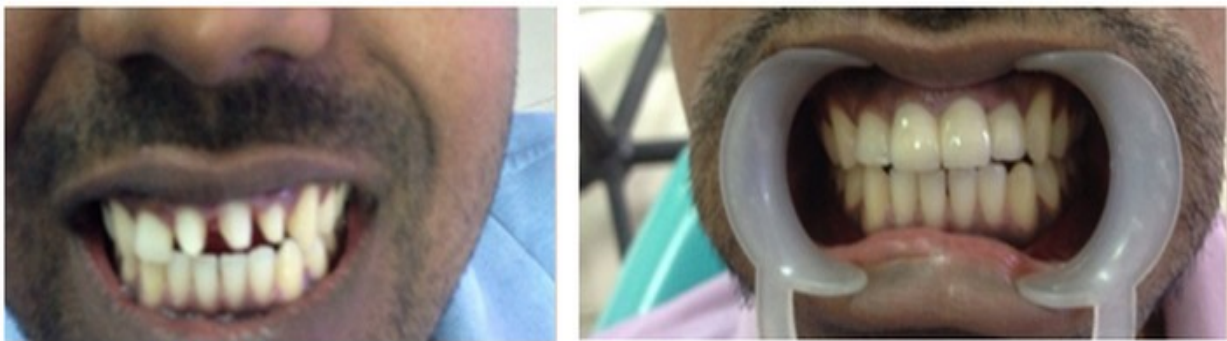The patient was also co-operative and understood what Dr. Shetty was conveying when he was suggested to go in for a complete smile design from first premolar-premolar as he had a wide smile line instead of the usual canine to canine makeover for the perfect result he was looking for. He was so happy with the trial result itself that no further changes were required.



CASE 2: **Chipped, Broken Front Teeth**

This was a young patient who was perfectly happy with his teeth until an accident **chipped** of his two front teeth and **broke** one altogether. He had been avoiding treatment as he was depressed thinking of bulky artificial crowns most had and thought he would rather have these teeth instead! After being made aware of the latest metal-free ceramic and Zirconia crowns he was ready to go for the treatment but did not want to correct the slight protrusion of the adjacent tooth and infact wanted the 3 new teeth to blend naturally.

Here the challenge was to match the shade exactly to that of the existing teeth as we were going for just 3 teeth and to make it look natural rather than the ideal alignment of teeth that is usually done. On slightly increasing the translucency, after looking at the first trial, the patient was very happy with the results.



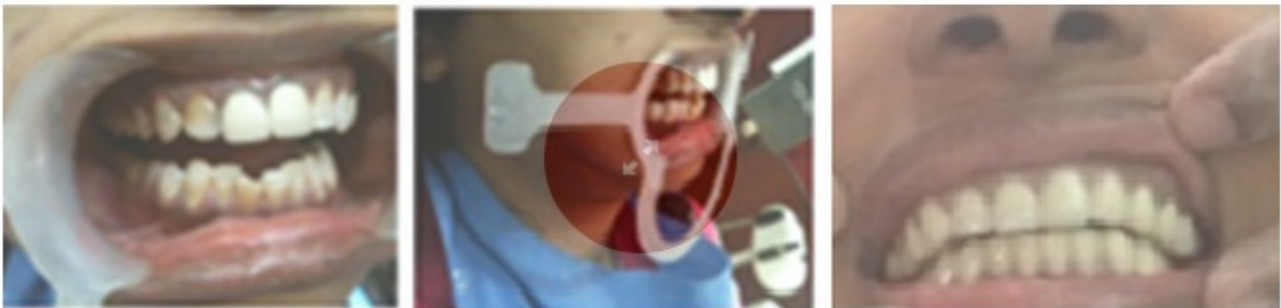CASE 3: **Fluorosis**

This young patient forever knew she had fluorosis and that she was having multiple decay and chipping off of teeth due to this problem. She had already undergone multiple root canals and crowning of teeth at different times in her life. She had come for a permanent solution and wanted to improve her smile at the same time, as she had just begun her career.

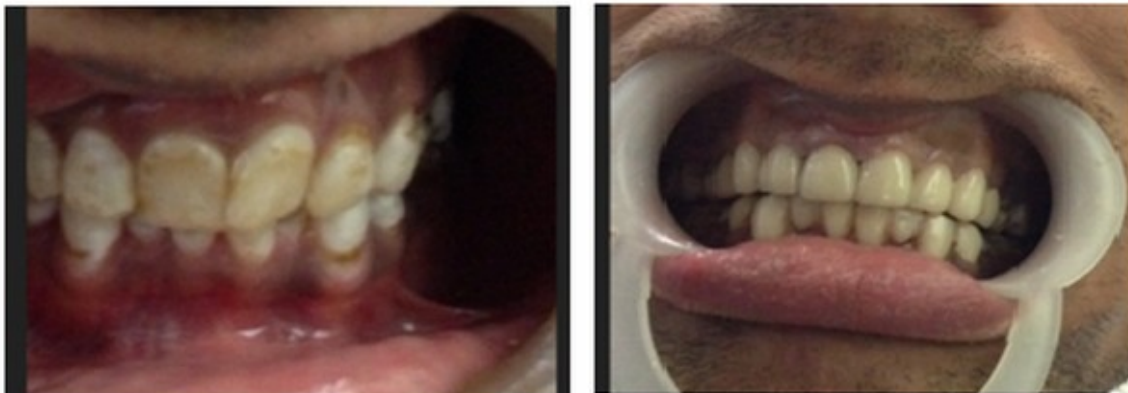This young patient forever knew she had fluorosis and that she was having multiple decay and chipping off of teeth due to this problem. She had already undergone multiple root canals and crowning of teeth at different times in her life. She had come for a permanent solution and wanted to improve her smile at the same time, as she had just begun her career.

In her case a thorough analysis was done using models and according to her budget a plan was worked out to correct her posterior teeth using (the latest Laser-sintered) metal ceramic crowns and since the gums were thin against her front teeth, metal free crowns were selected for the front four teeth so that they would last long without affecting the gums adversely. We were happy to manage to get her bite perfectly comfortable with her back teeth and her front teeth also corrected to her satisfaction within a weeks' time.

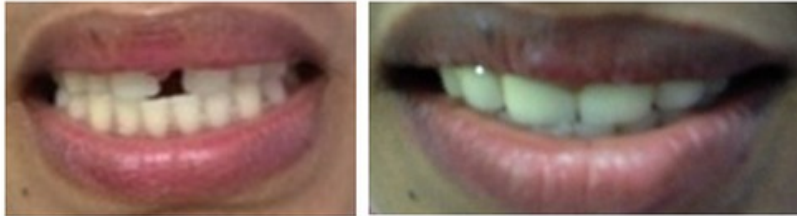Female Patient



Male Patient



CASE 4: Large Space

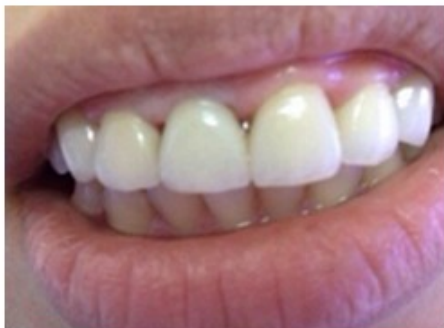

This patient had a **large space** between the front two teeth of more than 2-3 mm which is seen in normal **diastema** cases and had come with a time frame of 2 weeks to her engagement to have it corrected! Photographic and model examination put it at almost 5-6 mm and she had come with the intention of getting it closed by altering only the front two teeth and did not want to touch the other teeth. It was a challenge to convince the patient that two teeth if used to close such huge gap would not give the desired esthetic results and in her case a minimum of four teeth would be required to equally proportion them. On the third day, at the trial, she confided happily that this was exactly what was in her thoughts and the work was cemented.

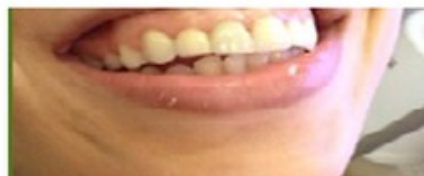
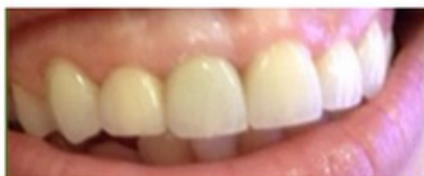
CASE 5: Gum Recontouring with Smile Design to Replace Old Crowns

Pre-Treatment



Post Treatment



This patient had already got crowns to make her teeth look better but she was still conscious and unhappy with her smile altogether though she got the best available crowns and she thought nothing could be done about it now.

In a free smile-makeover consultation for her she was made aware that firstly there were much superior materials for crowning front teeth and in her case gum recountouring followed by smile designing with flatter rectangular teeth would be required for a pleasant result and that all her problem areas with her smile could be corrected in about two- three weeks' time if she desired and told her to research about the information we had given her. A week later she suggested she would like to go ahead with her smile makeover and had already kept her calendar free for the coming two weeks.

This was a wonderful case in itself because we could meet the patient's expectations and the dramatic changes seen not only in her teeth but her body language and the way she smiled itself. Firstly, laser gum recountouring of her first 6 teeth were done and the old crowns were removed; artistically reshaping her teeth for the new crowns; all in the first sitting itself under anesthesia. Then we placed temporary teeth leaving it for 10 days for gums to start healing. The impressions for the permanent crowning were taken at the 14th day and by the 18th day she had a bright smile in place that she said she never thought feasible.

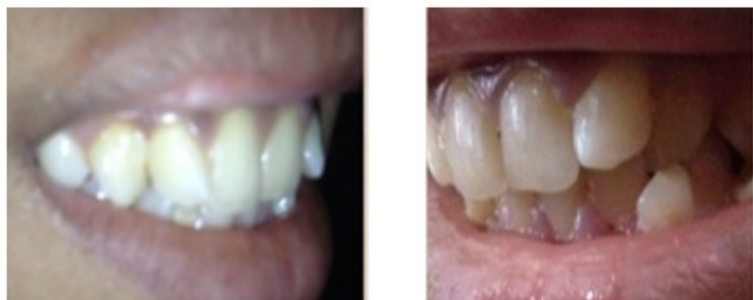■ CASE 6: **Protruded**

This girl had a narrow arch alignment of teeth which resulted in two front teeth being so **protruded** that she was finding it difficult to close her lips and her mother complained that she never smiled and felt shy to even speak to people because of this problem. As her wedding was due she did not have the time for correction using braces. Her budget did not permit her to go for a complete smile design and she requested if we could just correct this in the best possible manner.

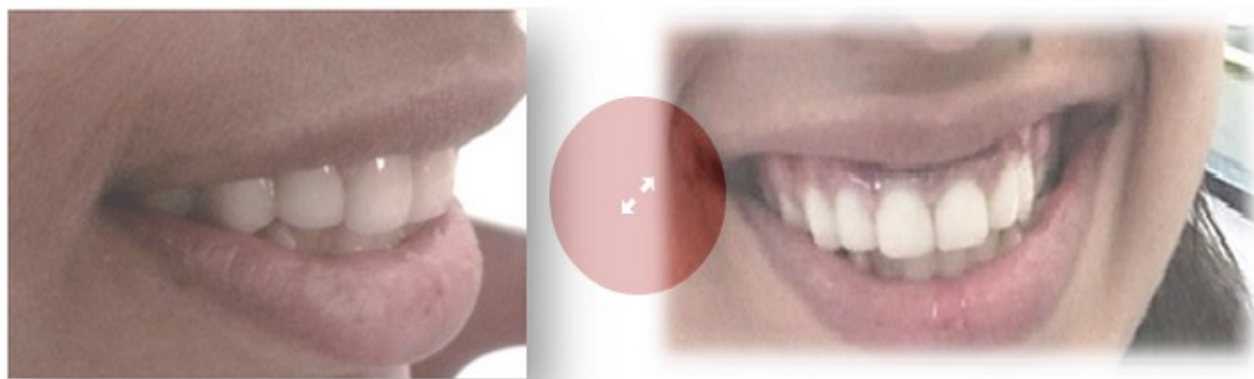


We went in for a combination of metal free ceramic crowns and veneers to get the desired results and managed to get the ideal smile without involving the premolars. We gave a pleasant shade to merge with the behind natural teeth and also gave the option of going in for the pre molars at a later date if she desired.

Pre Treatment



Post Treatment



CASE 7: **Quality of Crowns/Old Crowns to New**

This patient Mr. Hajee had come to our set up months ago stating he had undergone crowns treatment and in fact got a picture from a magazine asking why his teeth are looking ugly while it's so wonderful in this picture!

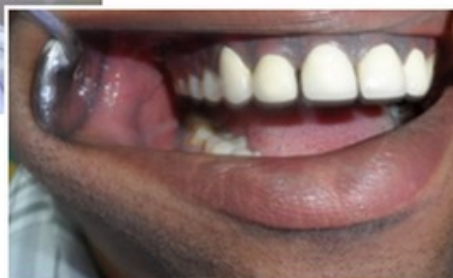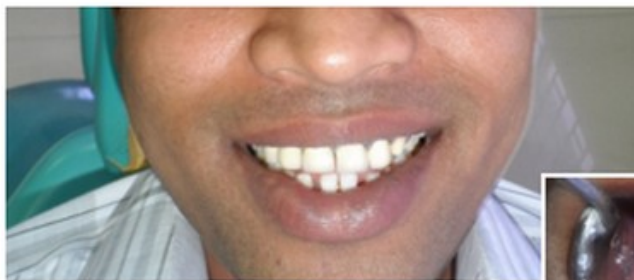He said he had chipped off his four front teeth and he went to a nearby dentist who helped him get metal-fused porcelain crowns for the maxillary anterior teeth spanning from right canine to left canine. He was really disappointed with the esthetics of the metallic tinge that it gave to his smile. He was embarrassed to smile in front of anyone.

The classic solution to address the issue was to replace the 6 unit metal-fused porcelain crowns with highly esthetic **Metal-free crowns**. Due to its excellent biocompatibility, high esthetic value and very high strength, we have an immediate excellent cosmetic and functional post-operative result. This is important because, on one hand, the patient's cosmetic expectations should be addressed and on the other hand, neighboring tooth should not be affected and also should allow him to maintain his oral hygiene."

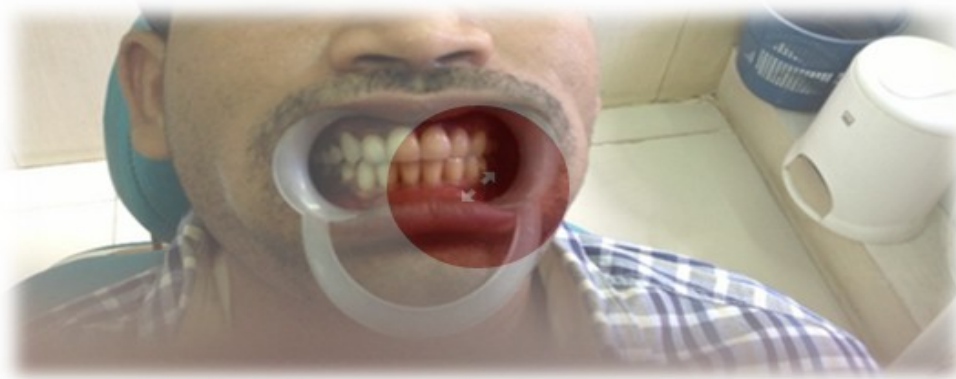In his case, there were two main challenges. The first was the careful removal of existing prosthesis without damaging the tooth inside; the second consisted of aligning the remaining tooth structure, which is the most important step, to impart the best esthetic results. He also required a round of deep cleaning of the gums to make it receptive to the new crowns.

Hajee, now has permanent high value biocompatible ,aesthetic e-max **crowns**, which in principle are no different than natural teeth in regards to function and appearance and if well cared for, will last for decades.

Pre-Treatment



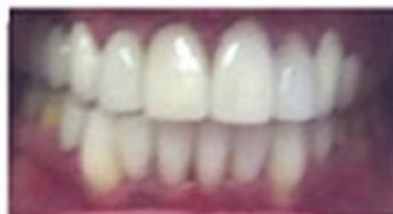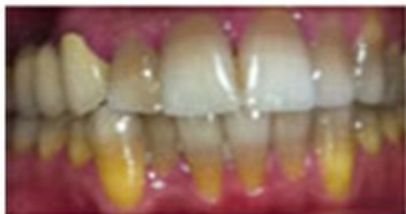Post Treatment



CASE 8: **Discoloration – Laminates and Lumineers**

In a similar case , this patient had what he knew to be **tetracycline stains** on all of his teeth and wanted to get it corrected .He already had a perfect alignment of the teeth.

The challenges we managed to overcome in this case were to preserve the tooth structure by



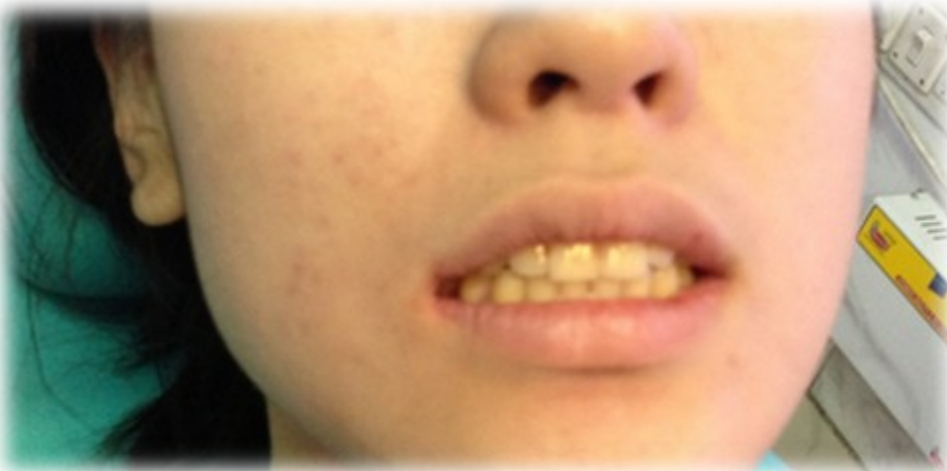going in for porcelain veneers (laminates) and at the same time mask the discoloration completely so that it would not show through the thin

veneers. Thus, we could meet the very high expectations of the patient who did not mind the expenditure as long as he could get the best that was there...

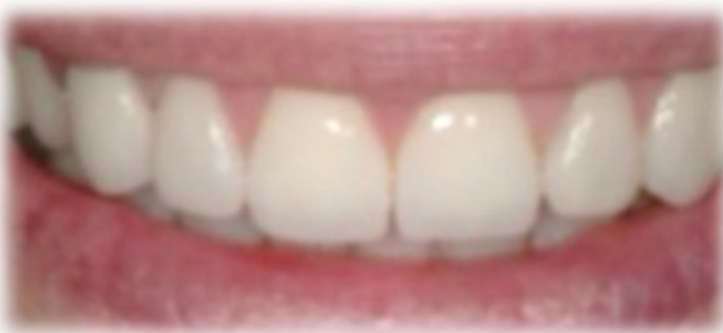

A Similar patient with discolored, **naturally yellow teeth** had undergone bleaching multiple times and wanted a permanent solution. She was advised for porcelain lumineers to get the best results. She was happy with the resultant bright smile at minimal shaping of tooth structure

Pre-Op



Post-Op

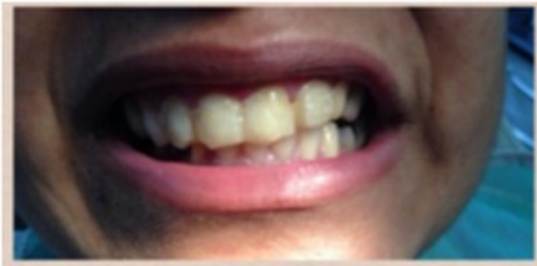

CASE 9: Deep bite/Age related wear-tear – Full mouth rehabilitation

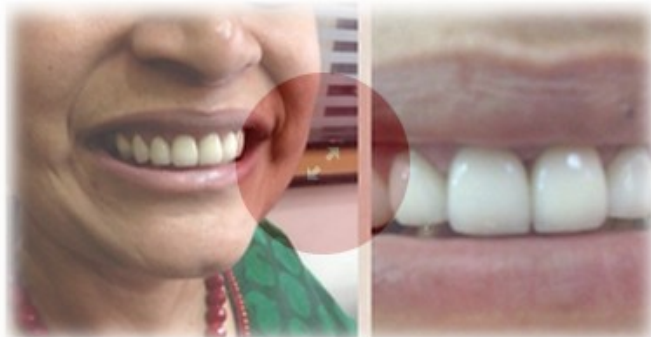Case 1: This professor in an established institute had come to us looking for a cosmetic and functional makeover at once so that she could have her teeth looking as they did 15 years ago when she was younger. She desired “natural looking set of pleasant teeth” to replace the present ones that had multiple composite fillings, and also her missing posterior teeth.

At her trial, she felt as she would like a brighter shade, and was happy with the rest. It was a small matter of within a day that the color was changed as per her wish and she felt satisfied with the final results.

Pre- Op

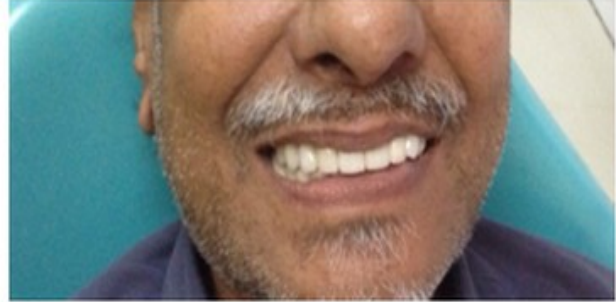
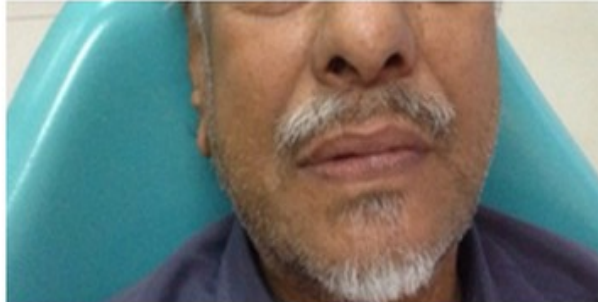
Post – Op

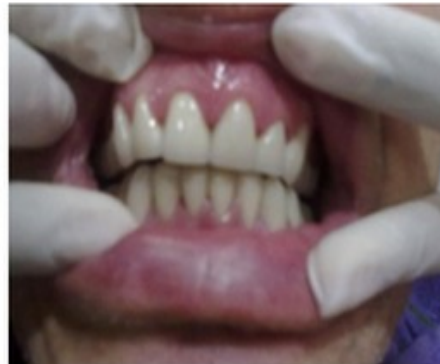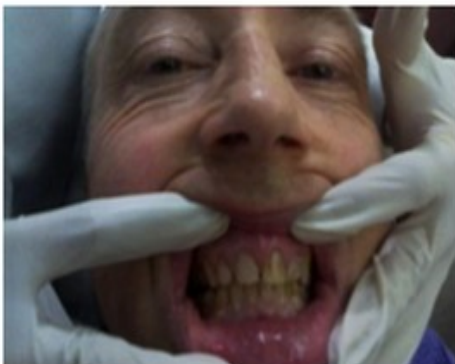


Case 2: In a similar case, this patient had not bothered to replace his missing back teeth since a long time and been using his front teeth for chewing that had resulted in collapse of the bite with severely attrited/worn out front teeth.

He was explained about the importance of the posterior teeth for overall hygiene maintenance and first posterior teeth were replaced to rise his bite and alongside the anterior teeth were restored to their past glory.



Case 3:



CASE 10: **Crowding / Rotation**

In this case, the patient had quite a bit of crowding of her front 6 teeth, and had come with her fiancée for a Cosmetic solution to having a great smile before her wedding due in four months. So, braces as an option that was given to her, she was unwilling to accept.

The accomplishments in her case was to give a perfect alignment within a smile line of front six teeth itself, without making it look protruding and to make it look natural so that she loses her inhibition of smiling... She was happy she went in for the high end Zirconia crowns as she realized it was an investment she would cherish for life.

